SHORT COMMUNICATION

Detection of apical root resorption after orthodontic treatment by using panoramic radiography and cone-beam computed tomography of super-high resolution

Alexander Dudic,[a] Catherine Giannopoulou,[b] Michael Leuzinger,[c] and Stavros Kiliaridis[d]
Geneva and Winterthur, Switzerland

Introduction: Apical root resorption is an adverse side effect of orthodontic treatment. We compared panoramic radiography (OPT) with cone-beam computed tomography (CBCT) in evaluating orthodontically induced apical root resorption. **Methods:** The study sample comprised 275 teeth in 22 patients near the end of orthodontic treatment with fixed appliances. Two calibrated examiners assessed blindly the presence or absence and the severity of apical root resorption on the OPT images after treatment and the corresponding reconstructed CBCT images. Resorption was evaluated as no, mild, moderate, severe, and extreme. **Results:** On the OPT images, 17 teeth (6.2%) could not be evaluated. Statistically significant differences were found between the 2 methods: 56.5% and 31% of the teeth showed no resorption by OPT and CBCT, respectively; 33.5% and 49% of the teeth showed mild resorption, whereas 8% and 19% showed moderate resorption by OPT and CBCT, respectively. Severe resorption was found in only 2 teeth by CBCT. **Conclusions:** Apical root resorption after orthodontic tooth movement is underestimated when evaluated on OPT. CBCT might be a useful complementary diagnostic method to conventional radiography, to be applied when a decision on continuation or modification of the orthodontic treatment is necessary because of orthodontically induced root resorption. (Am J Orthod Dentofacial Orthop 2009;135:434-7)

External apical root resorption is a common undesirable side effect of orthodontic treatment. The clinical diagnosis is based mainly on routine radiographic procedures, such as panoramic (OPT) and periapical radiography. However, some root shortening is required before it is detectable on the radiograph. Furthermore, OPT has been shown to overestimate the amount of tooth loss by 20% or more compared with periapical radiography,[1] and digitized periapical radiographs have been shown to underestimate apical root resorption compared with a micro-computed tomography scanner.[2] Until now, there was no gold standard for the detection of orthodontically induced root resorption.

Cone-beam computed tomography (CBCT) is a new radiographic method with application in several diagnostic areas, such as implant treatment, oral surgery, endodontic treatment, and tempomandibular joint imaging.[3-6] The great advantage of this technology is that offers 3-dimensional (3D) imaging of dental structures[7] and provides clear images of highly contrasted structures, such as bone.[4,6] Compared with conventional computed tomography, CBCT technology in clinical practice has important advantages such as minimization of the radiation dose, image accuracy, rapid scan time, fewer image artefacts, chair-side image display, and real-time analysis.[8] In orthodontics, CBCT imaging has been restricted to impacted teeth, temporomandibular joint visualization, determination of bone volume conducive to orthodontic tooth movement,[9-13] and cleft patients.[14] However, the diagnostic ability of CBCT in detecting orthodontically induced apical root resorption has not been sufficiently studied. The purpose of this study was to compare the efficacy of OPT and CBCT in the detection of apical root resorption after orthodontic tooth movement.

[a] Assistant professor, Department of Orthodontics, University of Geneva, Geneva, Switzerland.
[b] Assistant professor, Department of Periodontology, University of Geneva, Geneva, Switzerland.
[c] Private practice, Winterthur, Switzerland.
[d] Professor, Department of Orthodontics, University of Geneva, Geneva, Switzerland.
The present work was supported by the Swiss National Science Foundation (Grant No. 3200-112296). The authors report no commercial, proprietary, or financial interest in the products or companies described in this article.
Reprint requests to: Catherine Giannopoulou, Department of Periodontology, Dental School, University of Geneva, Rue Barthélemy-Menn 19, 1205 Geneva, Switzerland; e-mail, ekaterini.giannopoulou@medecine.unige.ch.
Submitted, July 2008; revised and accepted, October 2008.
0889-5406/$36.00

doi:10.1016/j.ajodo.2008.10.014

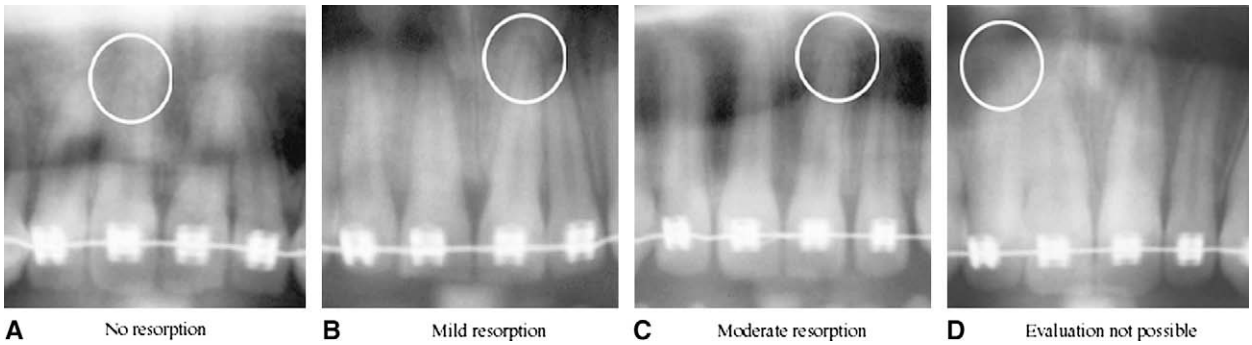

Fig 1. Index for evaluation of root resorption in the OPT: **A**, 0, no resorption in tooth 11; **B**, 1, mild resorption in tooth 21; **C**, 2, moderate resorption in tooth 21; **D**, evaluation impossible in tooth 12.

MATERIAL AND METHODS

Twenty-two patients (8 female, 14 male; mean age, 16.7 years; range, 12.6-37.2 years) were included in this study. They were selected from a private orthodontic practice in Winterthur, Switzerland. They were near the end of orthodontic treatment with fixed appliances and, after OPT evaluation, were further referred to study the proximity of neighboring roots with CBCT.

OPT images were acquired with the Orthopantomograph (Cranex Excel, Soredex, Tuusala, Finland) and stored in the TIFF format. The CBCT images were obtained with the 3D Accuitomo (J. Morita, Kyoto, Japan). Two sizes of imaging areas (40 × 40 and 60 × 60 mm) were used with super-high resolution (2.0 line pairs per millimeter; voxel size, 0.125 mm). The plane of primary reconstruction was aligned parallel to the long axis of the examined tooth by using iDixel software (J. Morita), as suggested by the manufacturer. Depending on the region of interest, either 1 or 2 CBCT images were taken from each patient.

Two calibrated examiners (A.D. and C.G.) assessed separately and blindly the presence or absence and the degree of apical root resorption in the OPT and CBCT images using the scoring system of Levander and Malmgren[15] that classifies it into 5 grades: 0, no root resorption; 1, mild resorption, with the root of normal length and only an irregular contour; 2, moderate resorption, with small areas of root loss and the apex having an almost straight contour; 3, severe resorption, with loss of almost one third of root length; and 4, extreme resorption, with loss of more than one third of the root length. In case of disagreement between the 2 examiners, a new evaluation was made, and this consensus was used for the final evaluation. The Cohen kappa showed substantial agreement between the 2 observers with the CBCT method (value, 0.63) and poor agreement with the OPT (value, 0.46).

Figures 1 and 2 show the grades of apical root resorption evaluated by the OPT and the CBCT, respectively. Only the grades found in our sample are shown.

The Pearson chi-square test was used to test the null hypothesis that there is no difference in evaluating apical root resorption on OPT and CBCT images. The statistical analysis was processed with SPSS software for Windows (release 13.0.0, standard version, SPSS, Chicago, Ill).

RESULTS

A total of 275 teeth were evaluated by OPT and CBCT for apical root resorption: 208 maxillary teeth and 67 mandibular teeth (92 incisors, 43 canines, 76 premolars, and 64 molars). Evaluation was impossible in 6 incisors, 4 canines, 5 premolars, and 2 molars with the OPT method. The comparison between the 2 methods was assessed in teeth evaluated by both methods; 258 teeth were assessed for statistical analysis.

The numbers and percentages of teeth with the different grades of apical root resorption as evaluated by OPT and CBCT are shown in Table I. Significant differences were observed between the 2 methods and for all grades of resorption. One hundred forty-five teeth were evaluated by OPT as having no resorption, whereas, by CBCT, only 80 teeth had no resorption; 92 teeth showed mild apical root resorption with OPT ad 128 teeth with CBCT. Only 21 teeth had moderate resorption with OPT, but 48 teeth had it with CBCT. Furthermore, 2 teeth had severe resorption-grade 3-when assessed with CBCT. Overall, the differences between the 2 methods in evaluating apical root resorption were significant for both the maxilla and the mandible (P <0.001 and P <0.002, respectively); the maxillary incisors showed the most pronounced differences (Table II).

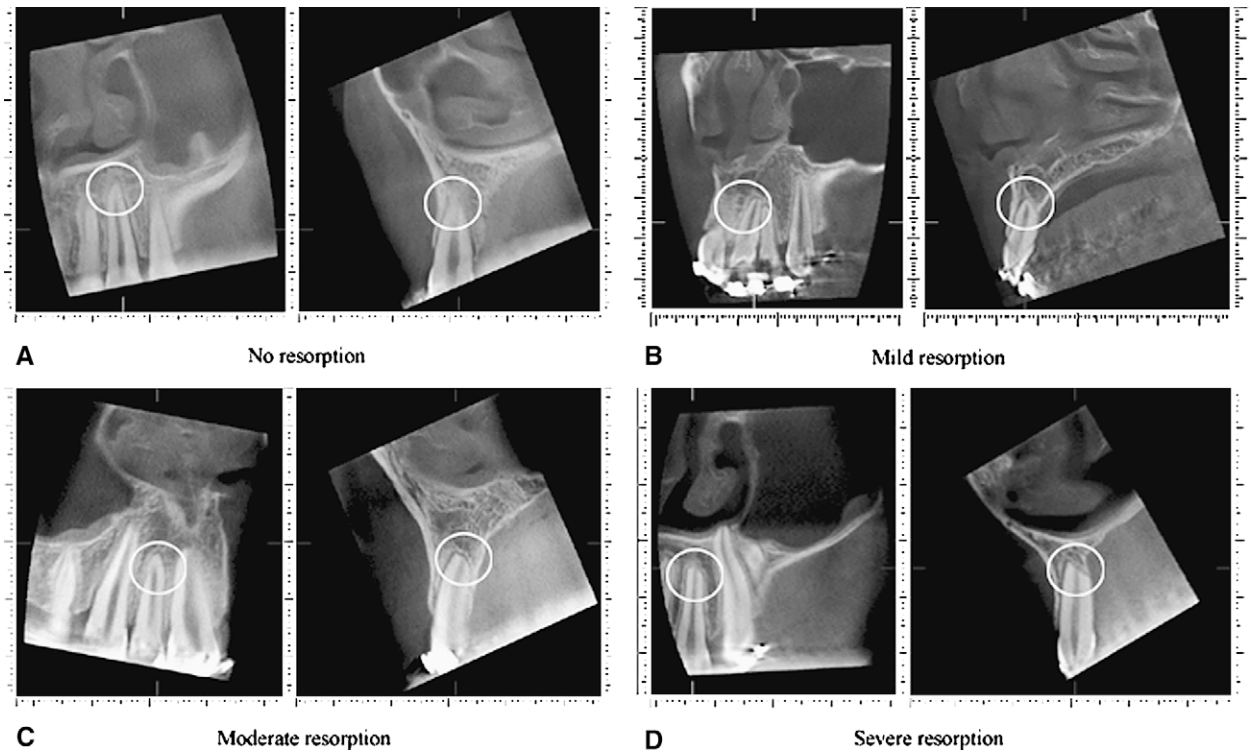

Fig 2. Index for evaluation of root resorption in the CBCT: **A**, 0, no resorption in tooth 22; **B**, 1, mild resorption in tooth 21; **C**, 2, moderate resorption in tooth 12; **D**, 3, severe resorption in tooth 22.

Table I. Evaluation of apical root resorption in all teeth by OPT and CBCT

	OPT			
	0	*1*	*2*	*Total*
CBCT				
0	62 (24%)	18 (7%)	0 (0%)	80 (31%)
1	70 (27%)	52 (20%)	6 (2%)	128 (49%)
2	12 (5%)	21 (8%)	15 (6%)	48 (19%)
3	1 (0.5%)	1 (0.5%)	0 (0%)	2 (1%)
Total	145 (56.5%)	92 (35.5%)	21 (8%)	258 (100%)

Table II. Evaluation of apical root resorption in maxillary incisors by OPT and CBCT

	OPT			
	0	*1*	*2*	*Total*
CBCT				
0	4 (6.2%)	5 (7.7%)	0 (0%)	9 (13.9%)
1	6 (9.3%)	20 (30.7%)	1 (1.5%)	27 (41.5%)
2	2 (3%)	16 (24.6%)	9 (13.9%)	27 (41.5%)
3	1 (1.5%)	1 (1.6%)	0 (0%)	2 (3.1%)
Total	13 (20%)	42 (64.6%)	10 (15.4%)	65 (100%)

DISCUSSION

A gold standard for the detection of orthodontically induced root resorption is still missing. However, this was beyond the goal of our study. Our aim was to determine the accuracy of OPT in the diagnosis of apical root resorption after orthodontic treatment. We compared the OPT findings with those obtained with CBCT: whereas 69% of the teeth were diagnosed as having apical root resorption by CBCT, only 44% showed apical root resorption with OPT. Furthermore, 17 teeth could not be evaluated by OPT. Overall, these results suggest that apical root resorption might be underestimated by OPT.

Root resorption is a 3D phenomenon, and its extent must be quantified with precision. Until now, radiographic methods, although they have important limitations, are the only methods to evaluate apical root resorption. However, the results need to be interpreted with caution. Only histologic or scanning electron microscopy studies can give exact results, but these are performed on experimentally moved and then extracted premolars.[16,17] By the OPT method, images of mandibular incisors proclined during treatment can be foreshortened or the apices might lie outside the focal plane, thus resulting in "shorter" teeth after treatment.[18] Furthermore, during orthodontic treatment,

the angulations of the incisors might change, and this can affect the length of the radiographic image of the tooth; thus, the amount of root resorption is not evaluated precisely.[19] Finally, the lack of reproducibility is also an important factor that limits the diagnostic accuracy of the OPT.[20]

CBCT provides highly detailed 3D imaging with only 1 x-ray exposure of approximately 18 seconds. Imaging can be obtained at any angle, thus offering optimum viewing and eliminating superimpositions. CBCT images have provided reliable data on root angulation[21] and the management of impacted canines.[9,13] The diagnostic ability of CBCT to detect simulated external root resorption was studied by Silveira et al.[22] Cavities of different depths and diameters were prepared on the cervical, middle, and apical thirds of the buccal surfaces. The evaluation of the CBCT's diagnostic ability showed high sensitivity and excellent specificity; only very small cavities in the apical third were more difficult to detect compared with other cavities.

For the moment, it is evident that CBCT cannot replace OPT, which remains the primary imaging modality. However, in certain complex cases, the 3D data sets might be more suitable than conventional radiographs. Thus, if signs of moderate root resorption are visible on OPT during the initial or middle phase of orthodontic treatment, CBCT can be useful in evaluating the severity of the situation to help make the decision on continuation and possible modification of orthodontic treatment.

We found that, compared with OPT, CBCT has an advantage in detecting root resorption during orthodontic treatment but has also has a greater medical risk. Therefore, CBCT imaging should be used for 2 main reasons: in research, it might increase our knowledge of root resorption, and, in clinics, CBCT images could help to monitor patients (with syndromes, agenesis, aberrant root forms) at risk for developing severe root resorption during orthodontic tooth movement.

CONCLUSIONS

CBCT is a powerful tool to show apical root resorption during orthodontic treatment, whereas OPT underestimates it. CBCT might be a useful complementary diagnostic method to conventional radiography, to be applied when determining whether to continue or modify orthodontic treatment because of orthodontically induced root resorption.

REFERENCES

1. Sameshima GT, Asgarifar KO. Assessment of root resorption and root shape: periapical vs panoramic films. Angle Orthod 2001;71:185-9.
2. Dudic A, Giannopoulou C, Martinez M, Montet X, Kiliaridis S. Diagnostic accuracy of digitized periapical radiographs validated against micro-computed tomography scanning in evaluating orthodontically induced apical root resorption. Eur J Oral Sci 2008;116:467-72.
3. Lascala CA, Panelly J, Marques MM. Analysis of the accuracy of linear measurements obtained by cone beam computed tomography (CBCT-NewTom). Dentomaxillofac Radiol 2004;33:291-4.
4. Ziegler CM, Woettche R, Brief J, Hassfeld S. Clinical indications for digital volume tomography in oral and maxillofacial surgery. Dentomaxillofac Radiol 2002;31:126-30.
5. Danforth RA. Cone beam volume tomography: a new digital imaging option for dentistry. J Calif Dent Assoc 2003;31:814-5.
6. Sukovic P. Cone beam computed tomography in craniofacial imaging. Orthod Craniofac Res 2003;6(Suppl 1):31-6.
7. Marmulla R, Wörtche R, Mühling J, Hassfeld S. Geometric accuracy of the NewTom 9000 cone beam CT. Dentomaxillofac Radiol 2005;34:28-31.
8. Scarfe WC, Farman AG, Sukovic P. Clinical applications of cone-beam computed tomography in dental practice. J Can Dent Assoc 2006;72:75-80.
9. Liu DG, Zhang WL, Zhang ZY, Wu Yt, MA XC. Localization of impacted maxillary canines and observation of adjacent incisor resorption with cone-beam computed tomography. Oral Surg Oral Med Oral Pathol Oral Radiol Endod 2008;105:91-8.
10. Hatcher DC, Aboudara CL. Diagnosis goes digital. Am J Orthod Dentofacial Orthop 2004;125:512-5.
11. Holberg C, Steinhäuser S, Geis P, Rudzki-Janson I. Cone-beam computed tomography in orthodontics: benefits and limitations. J Orofac Orthop 2005;66:434-44.
12. Müssig E, Wörtche R, Lux CJ. Indications for digital volume tomography in orthodontics. J Orofac Orthop 2005;66:241-9.
13. Walker L, Enciso R, Mah J. Three-dimensional localization of maxillary canines with cone-beam computed tomography. Am J Orthod Dentofacial Orthop 2005;128:418-23.
14. Wörtche R, Hassfeld S, Lux CJ, Müssig E, Hensley FW, Krempien R, et al. Clinical application of cone beam digital volume tomography in children with cleft lip and palate. Dentomaxillofac Radiol 2006;35:88-94.
15. Levander E, Malmgren O. Evaluation of the risk of root resorption during orthodontic treatment. A study of upper incisors. Eur J Orthod 1988;10:30-8.
16. Owman-Moll P, Kurol J, Lundgren D. Continuous versus interrupted continuous orthodontic force related to early tooth movement and root resorption. Angle Orthod 1995;65:395-402.
17. Chan EK, Darendeliler MA, Petocz P, Jones AS. A new method for volumetric measurement of orthodontically induced root resorption craters. Eur J Oral Sci 2004;112:134-9.
18. Armstrong D, Kharbanda OP, Petocz P, Darendeliler MA. Root resorption after orthodontic treatment. Aust Orthod J 2006;22:153-60.
19. Apajalahti S, Peltola JS. Apical root resorption after orthodontic treatment—a retrospective study. Eur J Orthod 2007;29:408-12.
20. Rohlin M, Kullendorff B, Ahlqwist M, Stenström B. Observer performance in the assessment of periapical pathology: a comparison of panoramic with periapical radiography. Dentomaxillofac Radiol 1991;20:127-31.
21. Peck JL, Sameshima GT, Miller A, Worth P, Hatcher DC. Mesiodistal root angulation using panoramic and cone beam CT. Angle Orthod 2007;77:206-13.
22. Silveira HL, Silveira HE, Liedke GS, Lermen CA, Dos Santos RB, Figueiredo JA. Diagnostic ability of computed tomography to evaluate external root resorption in vitro. Dentomaxillofac Radiol 2007;36:393-6.