

Development of imaging selection criteria and procedures should precede cephalometric assessment with cone-beam computed tomography

Allan G. Farman^a and William C. Scarfe^b

Louisville, Ky

Cone-beam computed tomography (CBCT) systems for craniofacial imaging are now available from several manufacturers. CBCT potentially provides opportunities for 3-dimensional cephalometrics in orthodontic assessment of bony landmarks and air-bounded surfaces such as the facial skin. Two-dimensional cephalogram simulation could facilitate the transfer of growth projections from existing data sets as a starting point for use of a new 3-dimensional paradigm. Three methods are described to simulate conventional 2-dimensional cephalograms from CBCT images and volumetric data sets. However, certain precautions are required to assure that selection criteria and imaging parameters guarantee a radiation dose that is as low as reasonably achievable. (*Am J Orthod Dentofacial Orthop* 2006;130:257-65)

For more than half a century, 2-dimensional (2D) cephalograms have been used to assess skeletal and dental relationships in orthodontics. With the increasing availability of maxillofacial cone-beam computed tomography (CBCT), 3-dimensional (3D) assessments are now feasible. The cone-beam technique uses a single rotational scan of an x-ray source and a reciprocating x-ray sensor attached by a U- or C-arm around the patient's head to acquire many single-projection, or basis (raw), images. The entire scan therefore comprises many single-projection images, similar to cephalometric radiographs, each slightly offset in beam-geometry rotation (Fig 1).

CBCT units reconstruct the primary projection frames to provide standard viewing displays of coronal, sagittal, and axial correlational secondary slice images, similar to traditional computed tomography data display. All proprietary software is capable of various real-time advanced image display modes, derived from

the original data set. These modes include linear and curved oblique multiplanar reformatted (MPR) sections perpendicular to the axial slices.

Manufacturers provide examples illustrating the value of CBCT in evaluating dental conditions related to orthodontics, including dental impactions and supernumerary teeth, and several authors have indicated that CBCT is useful in assessing maxillofacial growth and development.¹⁻⁴ Although CBCT imaging is becoming commonplace in certain regions of the United States, its application to produce 2D cephalometric images has not been reported in detail. Moreover, although there are substantial databases that have validated traditional cephalometric analyses, this is not yet the case for 3D approaches.^{1,5-7}

Excellent dosimetry conducted by Ludlow et al⁸ showed that exposure from CBCT varies considerably between manufacturers' equipment and with and without thyroid-gland shielding. These authors indicated that CBCT exposure can be greater than a typical panoramic radiographic exposure. Furthermore, although thyroid shielding can be achieved when using a dosimetry phantom, this might not be possible when imaging the mandible in vivo, because of the beam geometry of CBCT.

We previously demonstrated linear measurement accuracy of CBCT images between selected anatomical points on dry skulls (iCAT, Imaging Sciences International, Hatfield, Pa) with the "truth" measured using a vernier caliper.⁹ The purposes of this article were to (1)

¹From the Department of Surgical and Hospital Dentistry, School of Dentistry, University of Louisville, Louisville, Ky.

^aProfessor of radiology and imaging science.

^bAssociate professor of radiology and imaging science, Division of Radiology and Imaging Science.

Reprint requests to: Dr Allan G. Farman, Division of Radiology and Imaging Science, Department of Surgical and Hospital Dentistry, University of Louisville School of Dentistry, 501 S Preston St, Louisville, KY 40292; e-mail, agfarm01@louisville.edu.

Submitted, August 2005; revised and accepted, October 2005.

0889-5406/\$32.00

Copyright © 2006 by the American Association of Orthodontists.

doi:10.1016/j.ajodo.2005.10.021

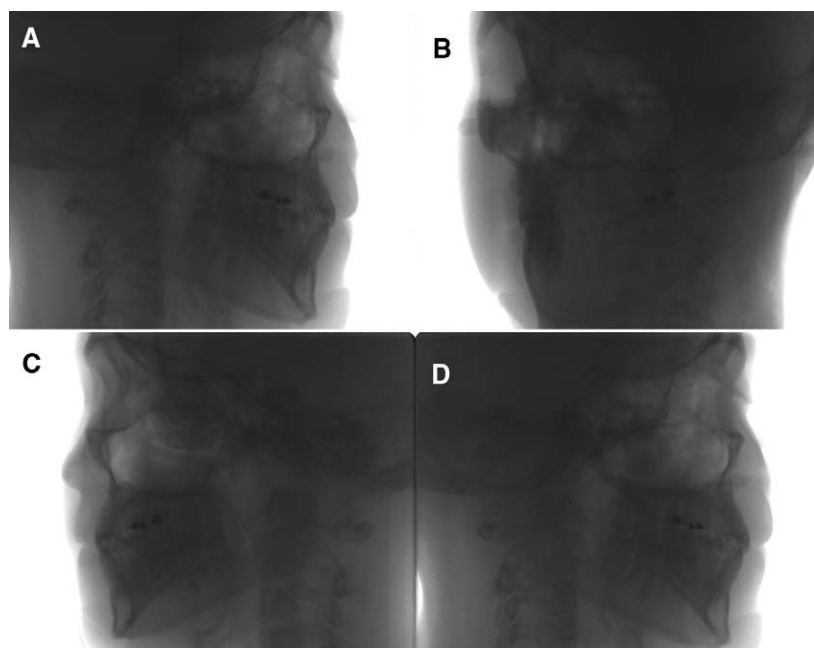


Fig 1. Four basis-image frames from 306 that comprise primary data for iCAT CBCT for 20-second full scan: **A**, frame 1, first basis image; **B**, frame 75; **C**, frame 152; **D**, frame 306, final basis image. Each image is approximately equivalent to individual cephalogram.

demonstrate 3 methods for creating 2D cephalograms from CBCT volumetric data sets so that direct comparisons can be made between existing 2D databases and the future paradigm of 3D analysis, and (2) urge the development of appropriate imaging sequence selection criteria to reinforce the “as low as reasonably achievable” (ALARA) principle to ensure that orthodontic patients are not unnecessarily exposed to ionizing radiation.

METHODS

With Institutional Review Board approval, anonymous CBCT image data sets were retrospectively analyzed. The imaging system used was an iCAT CBCT unit operating at 120 (± 5) kV and 3-8 ($\pm 10\%$) mA with a nominal focal spot of 0.5 mm and a source-to-detector distance of 67.5 cm. The image detector was an amorphous silicon/CsI flat panel measuring 20 x 25 cm with a front panel attenuation of less than 1 mm aluminum equivalent. Images were acquired at 12 bits in a single 360° rotation by using a 20-second exposure cycle. Although 10- and 40-second cycles are also available, the 20-second cycle was selected as a compromise between image quality and patient dose. For this cycle, in addition to a scout image to assure correct positioning, 306 basis images are made. These basis images are integrated with the help of back-

projection algorithms to form the CBCT image volume data set. The scan dimensions exceeded 17 x 13.3 cm. The voxel dimension selected was 0.4 mm for patients referred for imaging based on assessed clinical need. The minimum voxel size is 0.25 mm; however, the lower spatial resolution of 0.4 mm was selected to minimize patient exposure. Primary reconstruction was achieved within 2 minutes for standard resolution. Secondary reconstructions were made in real time by using the iCAT (version 2.03) proprietary software. Images were stored as digital imaging and communications in medicine (DICOM) files.

Two-dimensional projection images were created by 3 methods. The first method involved the export of the lateral scout radiograph taken initially to confirm the patient’s positioning. The second method involved selecting the individual lateral and anteroposterior basis images with the least anatomic discrepancies between the right and left sides corresponding to lateral and posteroanterior cephalometric projections. The third technique involved manipulation of the volumetric data set. Each image was selected by using the proprietary software, copied, and imported into an image software program (PhotoShop, Adobe Systems, San Jose, Calif) for analysis.

The default image display mode provides axial, sagittal, and coronal planar images of 0.40-mm thick-

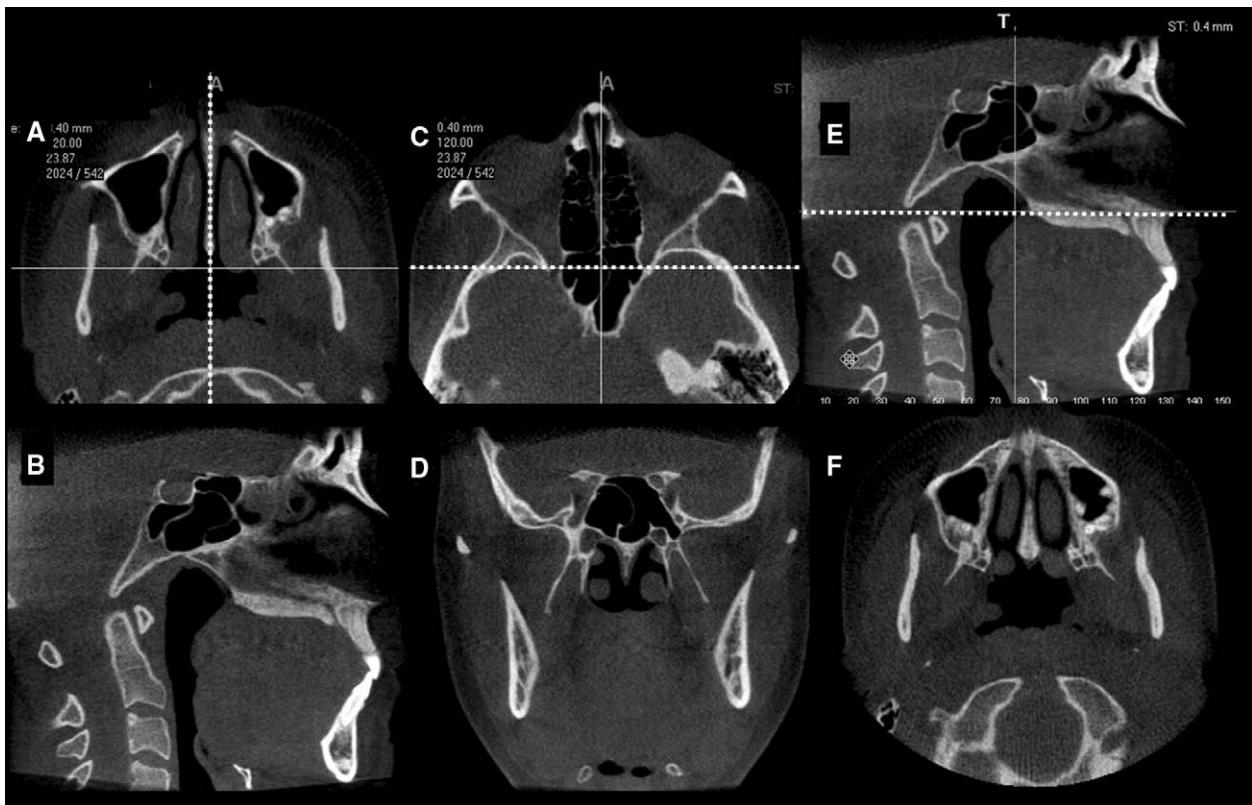


Fig 2. Reference plane positions used to create ray-sum 2D cephalometric projections: **A**, axial image at level of nasal fossa and foramen magnum with sagittal bisector (*dashed white line*) positioned to produce sagittal image (**B**); **C**, axial image at level of orbits with coronal bisector (*dashed white line*) positioned to produce coronal image (**D**); **E**, sagittal image from with axial bisector (*dashed white line*) positioned to produce axial image (**F**).

ness (minimum voxel linear dimension) with reference planes at the center of each image. Sagittal, coronal, and axial reference planes were positioned to bisect the patient's data set. For the sagittal images, the reference plane was adjusted on the axial image to coincide with the midpoint of sella turcica, parallel with the nasal septa, bisecting the foramen magnum. For the coronal images, the reference plane was adjusted on the axial image anteroposteriorly to intersect the posterior extent of the orbit. For the axial images, the reference plane was adjusted on the sagittal image to the level of the hard palate (Fig 2). If the patient was originally oriented incorrectly, the volume data set was reorientated so that specific anatomic features (eg, temporomandibular joints, orbits) in each projection were symmetrical and the plane of the hard palate was parallel. Two-dimensional cephalometric reconstructions were developed by increasing the slice thickness of each plane to a width of approximately 130 to 150 mm. This provided an image composed of the summed voxels, or a ray-sum image. Similarly, oblique MPR images along

the curve of the dental arch with variable slice thicknesses (0.40-150 mm) were individually created to provide a panoramic radiograph customized for each patient.

Numerous proprietary image enhancement algorithms were available to improve the visual esthetics of the images produced by each method. All algorithms were applied to the resultant images and observations recorded.

RESULTS

Each of the 3 methods replicated the 2D cephalometric projections. The scout method provided only a lateral cephalogram (Fig 3); the basis-image method provided both posteroanterior and lateral cephalometric images (Fig 3), and the ray-sum method, by using volumetric data, developed cephalometric images in all 3 orthogonal planes (Figs 3-6). After applying the image-enhancement options, subjectively we considered sharpening and edge filters to have the greatest potential in refining anatomic structures for interpreta-

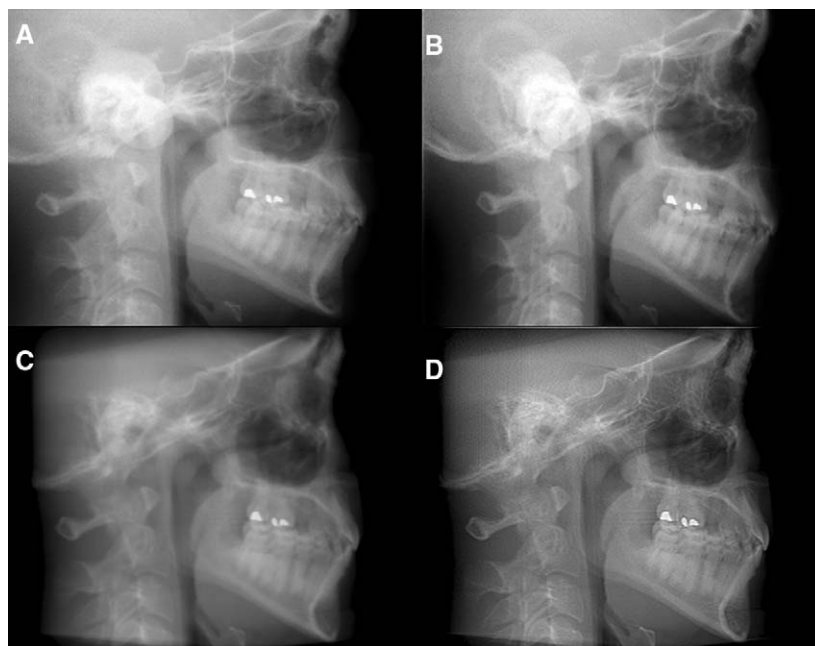


Fig 3. Simulated cephalometric image from **A**, export of scout image; **B**, inverted grayscale basis image; **C**, ray-sum image; **D**, sharpened, edge-enhanced ray-sum image.

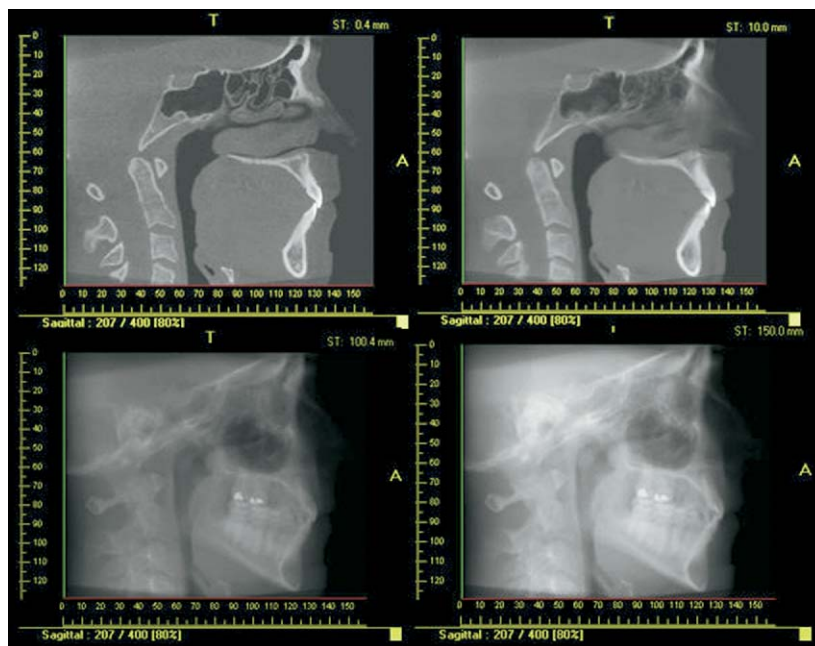


Fig 4. Construction of ray-sum simulated lateral cephalometric images from gradual increase in reference plane thickness of sagittal plane: *top left*, 0.4 mm; *top right*, 10 mm; *lower left*, 100.4 mm; *lower right*, 150 mm.

tion (Fig 3). In addition, the ray-sum method applied to a curved oblique projection created a simulated panoramic radiograph with the same image layer dimensions (Fig 7).

The major differences between the ray-sum images and either the scout or the basis-image method, or conventional cephalometric images, is that the projection is orthogonal, with equal magnification between

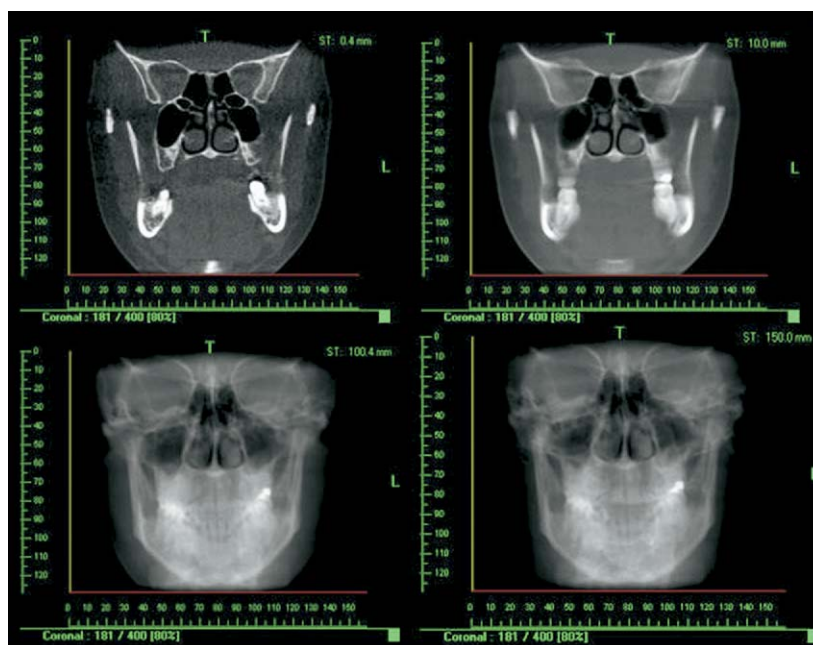


Fig 5. Construction of ray-sum simulated posteroanterior cephalometric images from gradual increase in reference plane thickness of coronal plane: *top left*, 0.4 mm; *top right*, 10 mm; *lower left*, 100.4 mm; *lower right*, 150 mm.

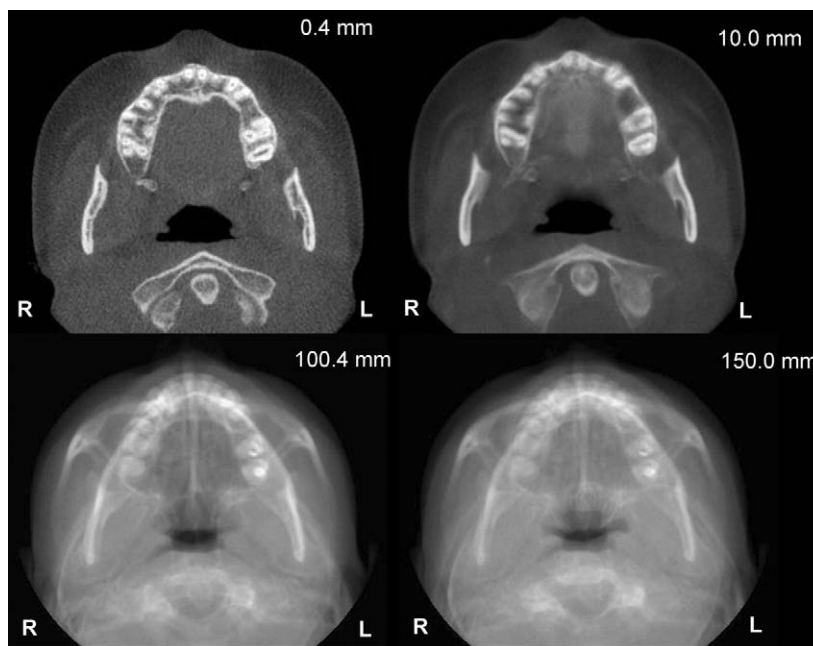


Fig 6. Construction of ray-sum simulated submentovertex images from gradual increase in reference plane thickness of axial plane: *top left*, 0.4 mm; *top right*, 10 mm; *lower left*, 100.4 mm; *lower right*, 150 mm.

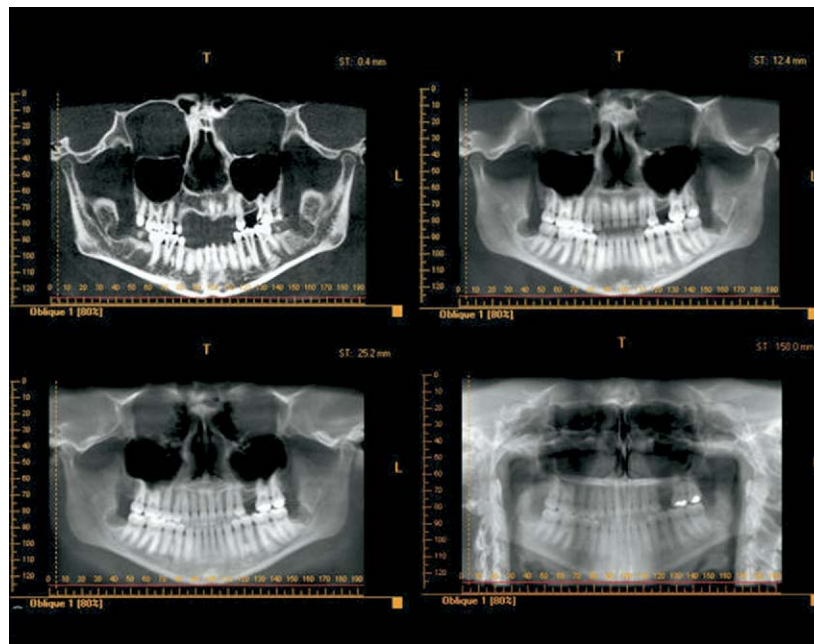


Fig 7. Construction of simulated panoramic images by increasing thickness of oblique curved MPR plane through mandibular dentition and ramus from *top left*, 0.4 mm; *top right*, 12.4 mm; *lower left*, 25.2 mm; *lower right*, 150 mm.

the beam's entrance and exit sides of the patient. Moreover, in each case, it was possible to produce slices equal to the dimension of the chosen voxel resolution; thus, anatomic superimposition could be removed to precisely define bony landmarks (Figs 4-6; *top left*). Unlike traditional methods, tooth dimensions and angulations were defined on CBCT without distortion (as demonstrated previously with anatomic specimens).

The matrix size of the exported images was 480 x 376 pixels both for scout and basis images (169 x 133 mm), producing a 167 kilobyte tiff file. Exported images were 72 dots per inch (dpi) in spatial resolution. The ray-sum images (108 x 91 mm) were 407 x 332 pixels with a tiff file size, uncompressed without layers, of 412 kilobytes, providing an image resolution of 96 pixels per inch.

DISCUSSION

Scout and basis-image techniques can be applied by using CBCT equipment to generate 2D simulated cephalometric images in 2 planes. However, varying corrected sagittal, axial, and coronal plane thicknesses on CBCT displays allows simulated 2D cephalographic projections from 3D data sets. These images can be exported and analyzed with third-party proprietary cephalometric analysis software. The ability to recon-

struct traditional cephalograms means that existing databases can still be used for orthodontic treatment projections. However, the nature of CBCT image acquisition underscores the inherent differences between conventional, scout, and basis images in producing projective cephalograms. The former produce images that have differential magnification between left and right structures, and the latter have uniform magnification because voxel resolution is isotropic (ie, equal in all 3 dimensions of the voxel). This might influence the accuracy of linear and angular cephalometric measurements.¹⁰ In addition, CBCT voxel isotropy enables reorientation of the volumetric data set so that the patient's head position can be realigned.

We observed that the proprietary "sharpen 3 x 3" algorithm subjectively produced images with optimal contrast, density, and sharpness, but the comparative diagnostic efficacy of its application is not known and requires further research.

Most screen-film systems used in film-based cephalometric imaging can achieve a resolution of 5 to 7 line pairs per millimeter, or 254 to 355 dpi. CBCT projection resolution is limited to the linear voxel dimensions. For the CBCT used in this study linear voxel dimensions were 0.40 mm, providing a theoretical resolution of approximately 1.25 line pairs per millimeter, or 64 dpi. However, the actual resolution of

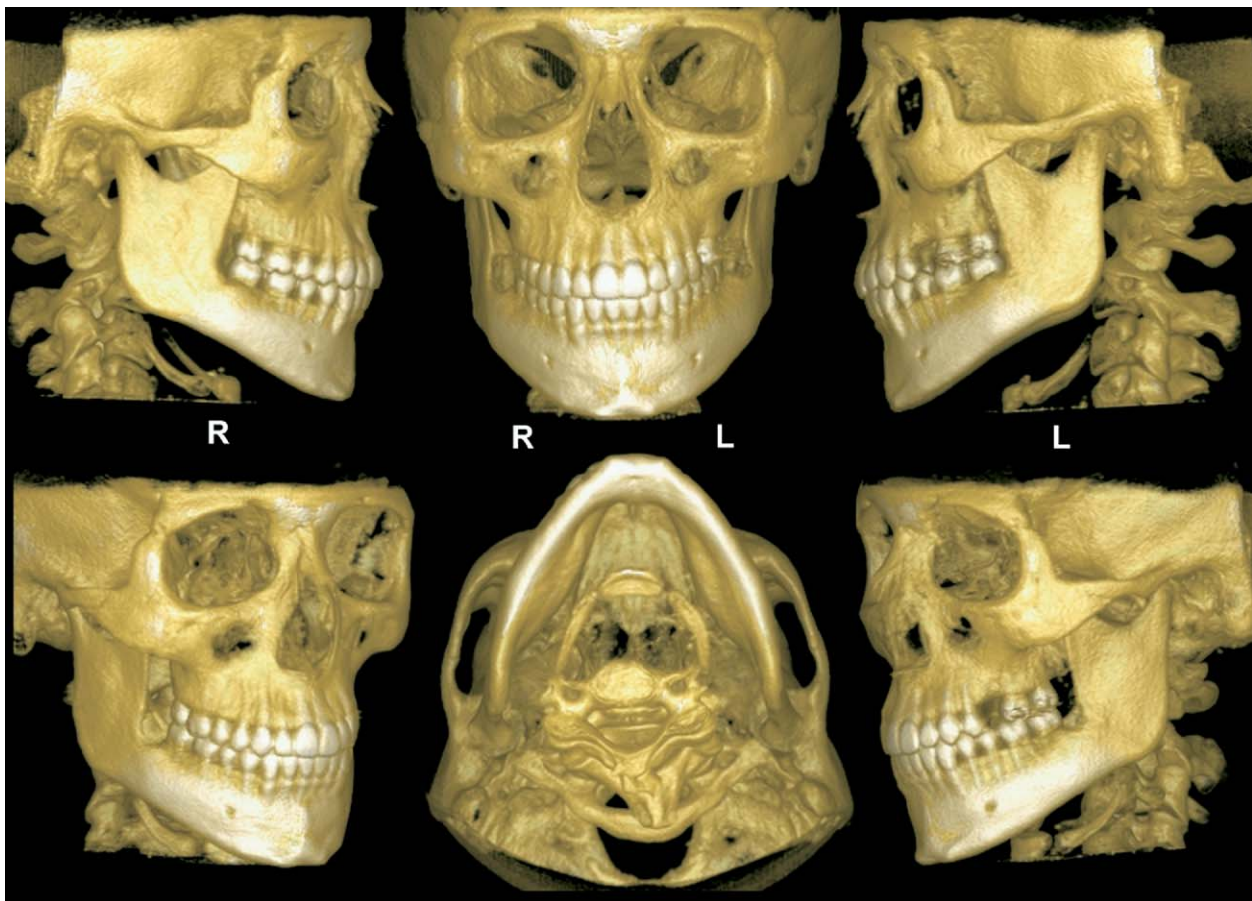


Fig 8. Surface-rendering reconstruction of iCAT CBCT data set (3DVR, Allovision, Greenville, SC) produces interactive volumetric image that can be manipulated to display bony surfaces of maxillofacial complex from various standard orientations.

the exported images was slightly higher at 72 dpi. The nature of this image extrapolation is unknown. The effect of this resolution on subsequent analysis might influence the reproducibility¹² and accuracy of cephalometric measurements.¹¹⁻¹³

Most CBCT units are capable of variable scanning fields of view. CBCT-derived 2D cephalometric projections are limited to equipment that can image from nasion to gnathion vertically and from zygoma to zygoma coronally. Commercial units capable of acquiring data volume sets suitable for the creation of 2D projections currently include iCAT, CB Mercuray (Hitachi Medical Corp, Kashiwa-shi, Chiba-ken, Japan), and NewTom 3G FOV 12 (Quantitative Radiology s.r.l, Verona, Italy), with 13.2, 19, and 20 cm, respectively.

Undoubtedly, orthodontic treatment planning will be refined because of more powerful 3D surface-rendering techniques such as volume rendering (Fig 8)

and maximum intensity profile algorithms (Fig 9). In addition, it is possible to replicate 3D volumes in part or all of the maxillofacial region, and to view these volumes from any plane (Fig 10).

Although soft-tissue definition with CBCT is sufficient to determine air/soft-tissue boundaries, including the patient's lateral profile, greater clarity of soft-tissue definition could improve the assessment of bulk and insertion patterns of the maxillofacial musculature that affects the stability of tooth position after orthodontic treatment. Obtaining the same scale of contrast with CBCT as is achievable with medical fan-beam computed tomography units might need increased doses, adjustments in detector specifications, and, perhaps, contrast media. The benefits of demonstrating soft-tissue details other than as air boundaries need to be balanced against the biologic risks.

Although the literature generally suggests that the radiation dosage for CBCT is within the order of

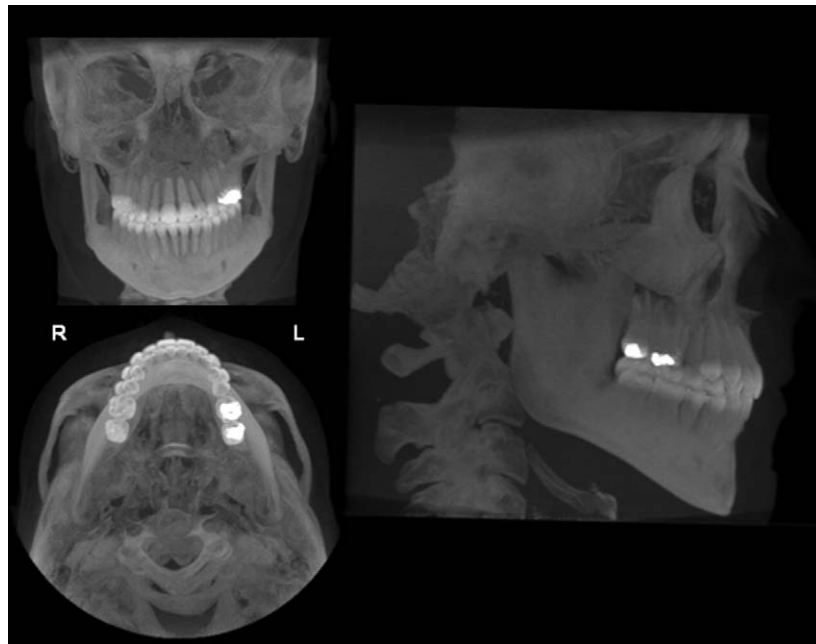

Fig 9. Application of maximum intensity projection algorithms to ray-sum projections provides surface representation of CBCT volumetric data set as posteroanterior, submentovertex, and lateral skull projections. Maximum intensity projection images show relationships of many elements (eg, angulation of tooth roots in alveolar bone) because of their transparent nature.

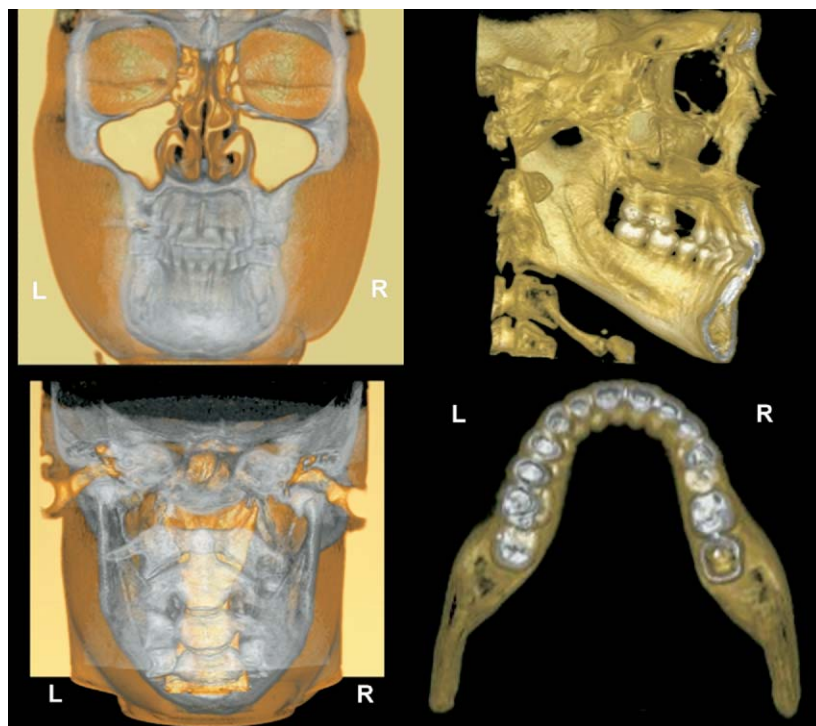


Fig 10. Surface- and volume-rendering techniques allow for integration of hard- and soft-tissue information of volumetric data. Surface images of selected sections of maxillofacial complex can also be produced, showing midsagittal cephalometric or segmented anatomy, enabling visualization of dental occlusion from axial perspective.

magnitude of several traditional film-based cephalograms and panoramic radiographs, these studies have been mainly in vitro and have not provided sufficient information about image selection, imaging frequency, image quality, and the need for remake of radiographic scans. Each CBCT is composed of several hundred basis images, each of which can provide 2D information comparable with traditional cephalograms. It behooves our specialty to examine ways to follow the ALARA principle when applying CBCT. Perhaps an answer is to use the CBCT scanner to provide very low dose traditional cephalometric projections and then to determine specific regions requiring full 3D rendition that can be tightly collimated to minimize the dose. It is also necessary to further examine the minimum number of basis images that are needed to provide information for orthodontic planning.

CONCLUSIONS

Several CBCT systems permit reconstructions that are comparable with traditional cephalometric projections. However, the diagnostic accuracy and efficacy of the images from CBCT must be compared with conventional cephalometric images. Potentially, however, existing databases regarding treatment projections can be used as a baseline to 3D cephalometric assessments. Evidence-based selection criteria should be developed for CBCT in orthodontics that take into account the ALARA principle.

REFERENCES

1. Sukovic P. Cone beam computed tomography in craniofacial imaging. *Orthod Craniofac Res* 2003;6(Suppl 1):31-6.
2. Aboudara CA, Hatcher D, Nielsen IL, Miller A. A three-dimensional evaluation of the upper airway in adolescents. *Orthod Craniofac Res* 2003;6(Suppl 1):173-5.
3. Baumrind S, Carlson S, Beers A, Curry S, Norris K, Boyd RL. Using three-dimensional imaging to assess treatment outcomes in orthodontics: a progress report from the University of the Pacific. *Orthod Craniofac Res* 2003;6(Suppl 1):132-42.
4. Maki K, Inou N, Takanishi A, Miller AJ. Computer-assisted simulations in orthodontic diagnosis and the application of a new cone beam x-ray computed tomography. *Orthod Craniofac Res* 2003;6(Suppl 1):95-101.
5. Mah J, Hatcher D. Current status and future needs in craniofacial imaging. *Orthod Craniofac Res* 2003;6(Suppl 1):10-6.
6. Halazonetis DJ. From 2-dimensional cephalograms to 3-dimensional computed tomography scans. *Am J Orthod Dentofacial Orthop* 2005;127:627-37.
7. Yamamoto K, Ueno K, Seo K, Shinohara D. Development of dento-maxillofacial cone beam x-ray computed tomography system. *Orthod Craniofac Res* 2003;6 (Suppl 1):160-2.
8. Ludlow JB, Brooks SL, Davies-Ludlow LE, Howerton WB. Dosimetry of 3 CBCT units for oral and maxillofacial radiology. Proceedings of the 15th Congress of the International Association of Dentomaxillofacial Radiology. Cape Town, South Africa; May 30-June 2, 2005.
9. Hilgers ML, Scarfe WC, Scheetz JP, Farman AG. Accuracy of linear temporomandibular joint measurements with cone beam computed tomography and digital cephalometric radiography. *Am J Orthod Dentofacial Orthop* 2005;128:803-11.
10. Chidiac JJ, Shofer FS, Al-Kutoub A, Laster LL, Ghafari J. Comparison of CT scanograms and cephalometric radiographs in craniofacial imaging. *Orthod Craniofac Res* 2002;5:104-13.
11. Ongkosuwito EM, Katsaros C, van't Hof MA, Bodegom JC, Kuijpers-Jagtman AM. The reproducibility of cephalometric measurements: a comparison of analogue and digital methods. *Eur J Orthod* 2002;24:655-65.
12. Halazonetis DJ. At what resolution should I scan cephalometric radiographs? *Am J Orthod Dentofacial Orthop* 2004;125:118-9.
13. Held CL, Ferguson DJ, Gallo MW. Cephalometric digitization: a determination of the minimum scanner settings necessary for precise landmark identification. *Am J Orthod Dentofacial Orthop* 2001;119:472-81.