ONLINE ONLY

Precision of cephalometric landmark identification: Cone-beam computed tomography vs conventional cephalometric views

John B. Ludlow, Maritzabel Gubler, Lucia Cevidanes, and André Mol
Chapel Hill, NC, and Miami, Fla

Introduction: In this study, we compared the precision of landmark identification using displays of multi-planar cone-beam computed tomographic (CBCT) volumes and conventional lateral cephalograms (Ceph).

Methods: Twenty presurgical orthodontic patients were radiographed with conventional Ceph and CBCT techniques. Five observers plotted 24 landmarks using computer displays of multi-planer reconstruction (MPR) CBCT and Ceph views during separate sessions. Absolute differences between each observer's plot and the mean of all observers were averaged as 1 measure of variability (ODM). The absolute difference of each observer from any other observer was averaged as a second measure of variability (DEO). ANOVA and paired *t* tests were used to analyze variability differences.

Results: Radiographic modality and landmark were significant at $P < 0.0001$ for DEO and ODM calculations. DEO calculations of observer variability were consistently greater than ODM. The overall correlation of 1920 paired ODM and DEO measurements was excellent at 0.972. All bilateral landmarks had increased precision when identified in the MPR views. Mediolateral variability was statistically greater than anteroposterior or caudal-cranial variability for 5 landmarks in the MPR views.

Conclusions: The MPR displays of CBCT volume images provide generally more precise identification of traditional cephalometric landmarks. More precise location of condylion, gonion, and orbitale overcomes the problem of superimposition of these bilateral landmarks seen in Ceph. Greater variability of certain landmarks in the mediolateral direction is probably related to inadequate definition of the landmarks in the third dimension.

Read the full text online at: www.ajodo.org, pages 312.e1-312.e10.

Am J Orthod Dentofacial Orthop 2009;136:312-3
0889-5406/$36.00

doi:10.1016/j.ajodo.2009.04.009

EDITOR'S SUMMARY

There have always been problems associated with conventional cephalograms, including errors in patient positioning, differential magnification of bilateral structures, and superimposition of craniofacial structures. So it should be no surprise that 3-dimensional (3D) computed tomography (CT) is increasingly used in maxillofacial surgery and orthodontics for various clinical and research purposes. But just how precise is landmark identification with cone-beam CT (CBCT) multi-planar reconstruction (MPR) displays compared with conventional cephalograms for presurgical orthodontic patients? These authors attempted to determine whether correlated axial, frontal, and sagittal MPR images provide more precise location of landmarks than conventional cephalometric radiographs.

Twenty presurgical orthodontic patients at the University of North Carolina were radiographed by using lateral cephalometric and CBCT techniques. The images were imported into Dolphin 2D (version 10) for viewing, and CBCT volumes were acquired with a NewTom 3 G. Preparation of the MPR images is technical, and you might want to study the details in the online version of this article. There could have been 3 sources of error in landmark identification in this study. First, in the MPR views, the landmarks require definitions for mediolateral localization in addition to the traditional anteroposterior and caudal-cranial directions. Second, some landmarks can be easily identified in 1 or 2 planes of space, but landmark identification in the third plane might be difficult. Observers in this study tended to locate the landmark in the planes of easy identification, disregarding the plane of difficult visualization. Third, selection of the best slice for landmark location in each direction requires time, calibration training, and careful assessment.

The authors concluded that identification of cephalometric landmarks was significantly more precise with the MPR views of CBCT volumes than with

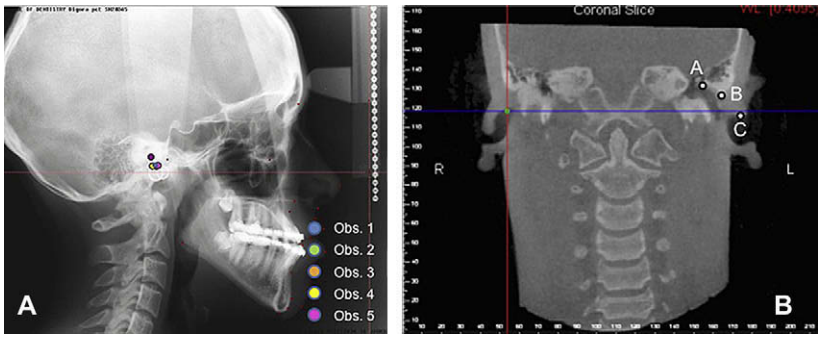

Fig 5. A, Conventional cephalogram showing observer variability in porion identification. Observers 1, 3, 4, and 5 appeared to be using the mechanical porion definition for their location, but observer 2 attempted to locate the anatomic porion. **B,** Coronal slice from the MPR view illustrating different ML and CC positions that might be used in identifying porion: *A,* highest bony segment of the auditory canal; *B,* most lateral segment of the bony auditory canal; *C,* most external segment of the soft-tissue component of the auditory canal; this corresponds most closely to the CC position of mechanical porion seen in the conventional cephalogram.

conventional lateral cephalograms, even when using traditional 2-dimensional (2D) definitions for these landmarks. The MPR views provided significantly more precise locations of condylion, gonion, and orbitale, overcoming the problem of superimposition of these bilateral landmarks in conventional cephalograms. It is commendable that the authors clearly discussed the possible application of CBCT technology in clinical practice and also cautioned against overuse or misuse of this technology.

Q & A

Editor: Do you see the need for additional studies to confirm your conclusions?

Ludlow: Certainly! As we move forward, we need to regularly look back to check our progress and reconfirm the validity of our direction. But future studies of 3D cephalometry also need to move on from here, using precisely defined landmark descriptions for the third dimension. As we compare these with their 2D counterparts, we are likely to find that some 2D landmarks are less precise or less useful for 3D analysis. New 3D landmarks will also be developed that have no counterparts in 2D analyses.

Editor: Do you think these findings will have an immediate impact on the use of imaging in orthodontic practice?

Ludlow: Studies such as this encourage the use and further development of CBCT cephalometry because they demonstrate backward compatibility with conventional cephalometric measurements and the potential for improved accuracy with the new technology.

Editor: Do you plan to use CBCT in your practice as addressed in this study? On what types of patients will it be most useful?

Ludlow: We are using volumetric cephalometry in treatment planning and follow-up of orthognathic surgery patients and those with severe asymmetry. The benefits of volumetric imaging for treatment planning and prediction are most evident in these patients; therefore, the benefit-cost ratio is easily justified. Until we have randomized clinical trials demonstrating improved treatment efficacy in uncomplicated orthodontic patients by using volumetric diagnostics, it will be hard to justify the expense and additional risk of these imaging devices routinely.